



REVIEW ARTICLE



WILEY

Topical stabilized hypochlorous acid: The future gold standard for wound care and scar management in dermatologic and plastic surgery procedures

Michael H. Gold MD, FAAD^{1,2,3,4} | Anneke Andriessen PhD⁵ |
 Ashish C. Bhatia MD, FAAD^{6,7} | Patrick Bitter Jr MD, FAAD⁸ |
 Suneel Chilukuri MD, FAAD, FACMS^{9,10} | Joel L. Cohen MD, FAAD, FACMS^{11,12} |
 Chris W. Robb MD, PhD¹³

¹Gold Skin Care Center, Nashville, TN, USA

²Tennessee Clinical Research Center, Nashville, TN, USA

³Vanderbilt University School of Nursing, Nashville, TN, USA

⁴School of Medicine, Meharry Medical College, Nashville, TN, USA

⁵Andriessen Consultants & Radboud UMC, Nijmegen, The Netherlands

⁶Northwestern University – Feinberg School of Medicine, Chicago, IL, USA

⁷Oak Dermatology, Itasca, IL, USA

⁸Advanced Aesthetic Dermatology, Los Gatos, CA, USA

⁹Refresh Dermatology, Houston, TX, USA

¹⁰Baylor College of Medicine, Houston, TX, USA

¹¹AboutSkin Dermatology and DermSurgery, Greenwood Village and Lone Tree, CO, USA

¹²University of California Irvine Department of Dermatology, Irvine, CA, USA

¹³Skin and Allergy Center, Spring Hill, TN, USA

Correspondence

Anneke Andriessen, Zwenkgras 25, 6581 RK Malden, The Netherlands.
 Email: anneke.a@tiscali.nl

Funding information

IntraDerm Pharmaceuticals, Grant/Award Number: The literature research for this review was supported

Abstract

Background: Hypochlorous acid (HOCl), a naturally occurring molecule produced by the immune system, is highly active against bacterial, viral, and fungal microorganisms. Moreover, HOCl is active against biofilm and increases oxygenation of the wound site to improve healing. Natural HOCl is unstable; through technology, it can be stabilized into an effective topical antiseptic agent.

Aim: This paper focuses on the use of topical stabilized HOCl in wound and scar management for pre-, peri-, and postprocedures—including its ability to reduce the occurrence hypertrophic scars and keloids. The role of the product in other skin conditions is beyond the scope of this article.

Methods: A panel comprising clinicians with experience in cosmetic and surgical procedures met late 2018 to discuss literature search results and their own current clinical experience regarding topical stabilized HOCl. The panel of key opinion leaders in dermatology and plastic surgery defined key insights and consensus statements on the direction of use for the product.

Results: Topical stabilized HOCl provides an optimal wound healing environment and, when combined with silicone, may be ideal for reducing scarring. Additionally, in contrast to chlorhexidine, HOCl, used as an antiseptic skin preparation, raises no concerns of ocular- or ototoxicity.

Conclusions: For wound care and scar management, topical stabilized HOCl conveys powerful microbicidal and antibiofilm properties, in addition to potency as a topical wound healing agent. It may offer physicians an alternative to other less desirable wound care measures.

KEYWORDS

hypertrophic scars, keloid scars, scar management, stabilized hypochlorous acid, wound care

1 | INTRODUCTION

A topical antimicrobial that decreases the bacterial bioburden of wounds without impairing the ability to heal is a therapeutic imperative.¹ Physicians who perform cutaneous, dermatologic, and aesthetic procedures are focused on rapid healing, minimum pain, and optimal appearance, including minimal scarring.² Therefore, wound care should prevent and treat infection, and minimize inflammation and scarring—all while the antiseptic and healing agent(s) used should be nontoxic to normal tissue.²⁻⁴

2 | HYPOCHLOROUS ACID

Stabilized hypochlorous acid (HOCl), in the form of a physiologically balanced solution (Figure 1),^{2,5} exhibits potent antimicrobial activities against a wide range of microorganisms as demonstrated in numerous studies.^{1,2,5-8} HOCl is a naturally occurring molecule produced by neutrophils to destroy pathogens with no evidence of microbe resistance.⁵ This powerful lack of microbe resistance plus proven safety vs normal cells make topical HOCl a particularly attractive option for surgical wound site antimicrobial activity, especially in cosmetic and medical dermatologic procedures targeting the face.^{2,9}

3 | ANTISEPTIC AGENTS FOR CUTANEOUS PREPARATION

Common antiseptics used for dermatologic, medical, and/or aesthetic procedures include isopropyl alcohol, povidone-iodine, and chlorhexidine.¹⁰ Isopropyl alcohol, although inexpensive, can cause irritation, is short acting, without enduring antimicrobial activity, and it is flammable. Povidone-iodine is rapidly effective, but neutralized by blood and sputum.¹⁰ As an antiseptic skin preparation, chlorhexidine is used extensively and provides highly effective antimicrobial presurgical skin cleansing.⁶ However, while chlorhexidine has a sustained antimicrobial effect, it has a potential risk of both ocular- and ototoxicity, especially to the middle ear.^{9,11} Significant risk of ocular toxicity exists particularly when chlorhexidine is used in peri-ocular areas, which presents a serious challenge to dermatologists, plastic surgeons, and other healthcare providers who treat facial areas.^{9,11} If chlorhexidine comes into contact inadvertently with the ocular surface, corneal damage can occur.¹¹

While no direct studies compare chlorhexidine with topical HOCl, no concerns about ocular toxicity with HOCl have been raised. In fact, HOCl was found to be nonirritating and nonsensitizing in various animal safety models.⁵ In a review article on chlorhexidine keratitis, Steinsapir and Woodward⁹ discussed ocular toxicity hazards with chlorhexidine, but did not mention the use of neutral super-oxidized agents such as HOCl.⁹ The panel recognized chlorhexidine's risk of ocular toxicity as a valid concern to physicians performing facial and cutaneous procedures requiring antiseptics and welcomed the safety profile of HOCl.

4 | ANTISEPTIC AGENTS FOR WOUND HEALING

Data confirm showing HOCl are a potent antimicrobial, a fast-acting anti-pruritic, and a potent anti-inflammatory.^{2,6,8,12,13} The panel agreed HOCl's ability to increase oxygenation ($TcPO_2$) at the wound site, while breaking down biofilm, is an important key differentiator to other products especially since studies show impaired healing results in chronic wounds or wound dehiscence.^{4,8}

5 | WOUND HEALING—A THREE-PHASE PROCESS

Wound healing is a complex process comprising a well-organized cascade of biological reactions within three interrelated phases—inflammation, proliferation, and remodeling.⁸ These phases involve an intricate progression of cytokines acting upon cellular and extracellular elements in epithelium and underlying mesenchymal tissue.⁴ Yet the phases are not discrete as proliferation begins even before inflammation is completed and continues even as remodeling begins (Figure 2).^{14,15}

In fact, while the bulk of remodeling is complete within the first year, the strength and appearance of a scar can continue to evolve thereafter.⁴ Due to this ongoing synthesis, wound care and healing must be considered a dynamic process, with minimized scar formation a long-term goal.¹⁴

Evidence suggests skin care immediately before procedure/surgery and throughout the healing phase can have significant effects on healing outcomes; therefore, pre-, peri-, and postoperative management of surgical wounds is crucial to prevent infection, to minimize scar formation, and to reduce the risk for other complications.¹² This is the panel reiterated where HOCl stands out.

6 | BACTERIA, BIOFILM, AND HOCL

Antimicrobial treatment in wound care poses a major challenge because of the creation of biofilm and resistance of microorganisms.¹⁶ Biofilm formation is thought to create a self-perpetuating cycle, prolonging the existence of macrophages and neutrophils in the wound, which in turn impairs normal wound healing and potentially reduces the effectiveness of innate immunological responses.¹⁷⁻¹⁹

However, one significant aspect of the immune system fighting against microorganisms is its ability to generate an effective and rapid response, including formation of highly reactive chemicals, such as hydrogen peroxide (H_2O_2), which is then converted into HOCl during neutrophil activation in the inflammatory phase of wound healing (Figure 3).^{8,20,21}

Numerous clinical studies show HOCl generates various effects to combat microbiotic organisms, including biofilm breakdown.^{8,22-24} Wang et al⁵ indicated HOCl exhibits broad-spectrum antimicrobial activity at concentrations ranging from 0.1 to 2.8 $\mu\text{g/mL}$ and verified

FIGURE 1 Hypochlorous acid at optimal pH levels. Adapted from Wang et al 2007⁵

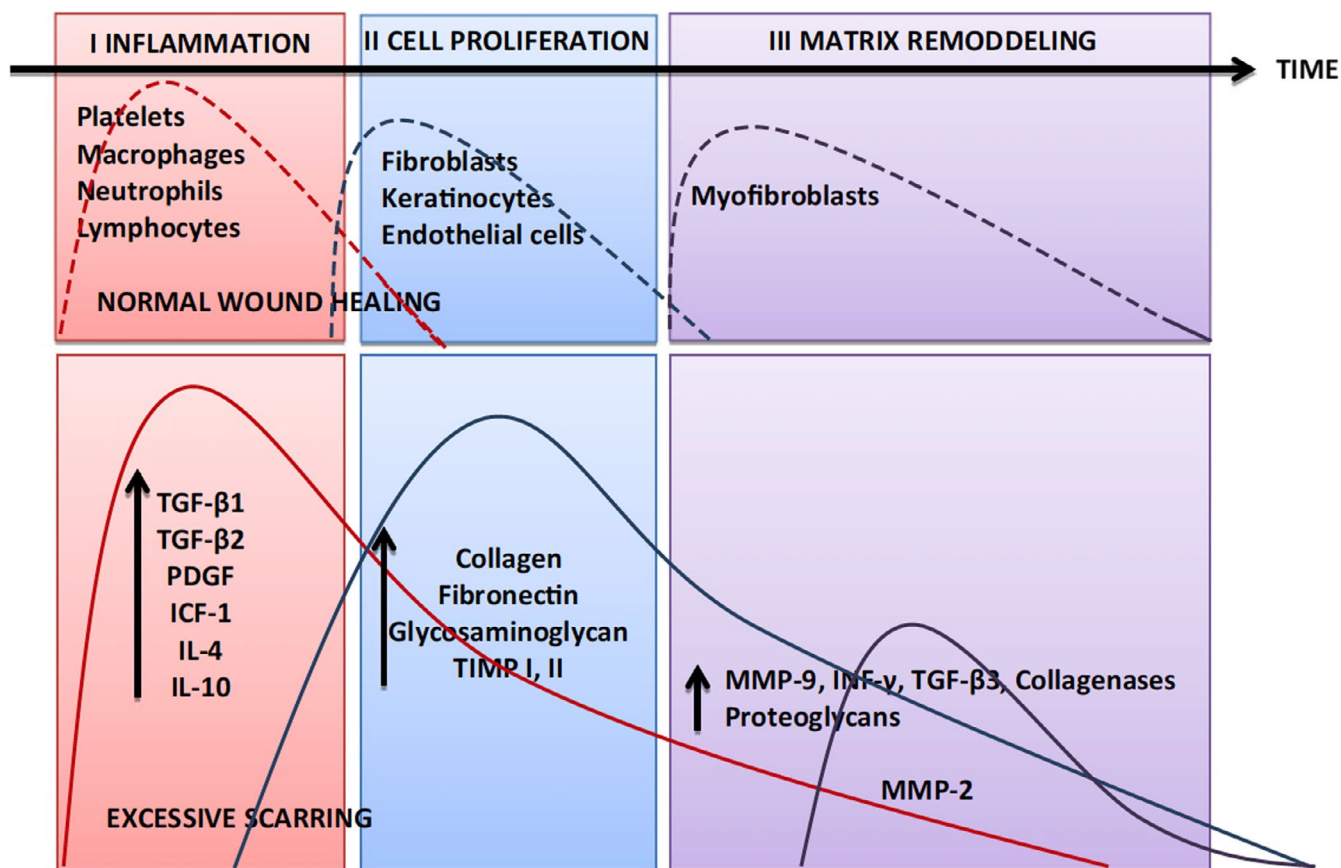
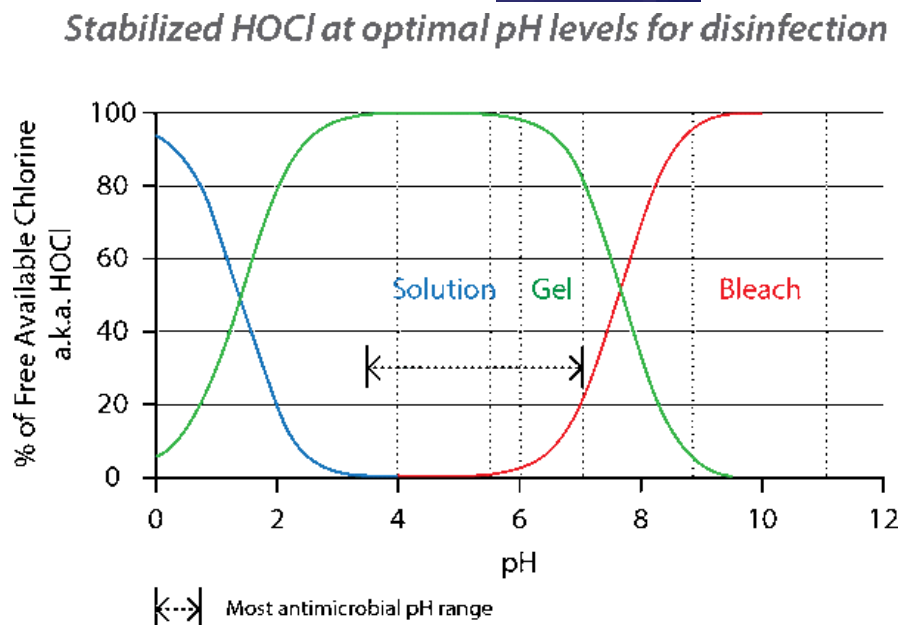


FIGURE 2 Normal wound healing phases vs excessive scarring. Adapted from Gauglitz et al¹⁵

its lethality against a wide range of microorganisms—with the majority of test organisms killed (>99.99%) within the first 2 minutes of exposure.⁵

Ortega-Pena et al²⁵ analyzed the effectiveness of different antiseptics to inhibit the various stages of biofilm formation and to

disrupt biofilm adhesion in vitro.²⁵ Results reveal chlorine-releasing agents exhibit immediate antibiofilm effects only in the short term but with some resistance,²⁵ while HOCl is shown to be effective in preventing biofilm formation within a short period of time yet demonstrates virtually no toxicity.²⁵

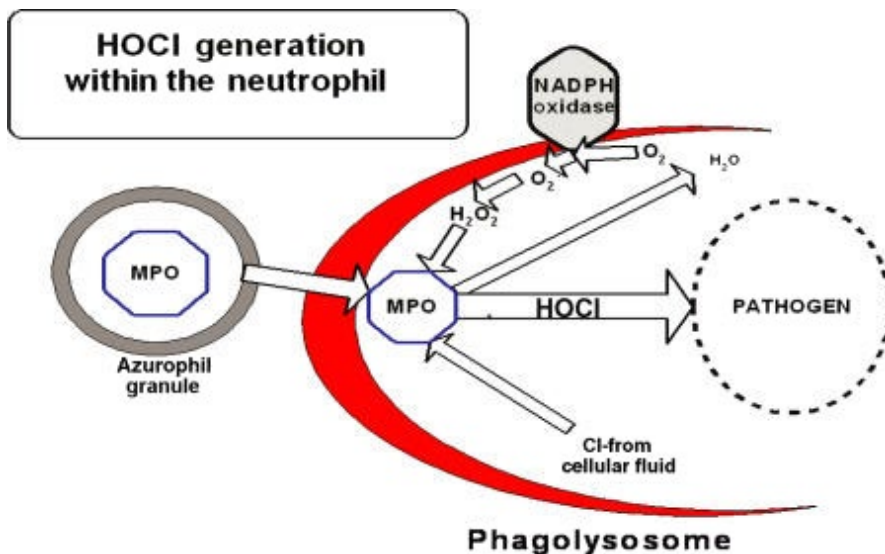


FIGURE 3 Microbicidal generation of HOCl. Adapted from Wang et al 2007⁵

7 | INFLAMMATION, ITCH, AND PAIN IN WOUND HEALING AND SCARS

7.1 | Inflammation

A significant portion of HOCl's potency is derived from its anti-inflammatory effects, which come from its effect on controlling mast cell response. As part of the immune response to proliferating microbes, mast cells flood the wound site, contributing to inflammation.

A study by Medina-Tamayo et al²⁶ suggests a neutral pH super-oxidized solution (SOS), such as HOCl, acts like a mast cell membrane stabilizing inhibitor, inhibiting the cell machinery for granule secretion without altering the signal transduction pathways induced by IgE-antigen receptor crosslinking.²⁶

Additionally, Sakarya et al⁸ demonstrated HOCl solution enhances wound healing in contrast to povidone-iodine, while a study by Dharap et al²⁷ showed HOCl provides significant improvements in ulcer wound size (and infection), as well as significant reduction in signs of inflammation.²⁷

7.2 | Pruritus and pain

Pruritus and accompanying pain are serious and significant concerns with wound healing and for subsequent scar management. Scratching can proliferate the itch/scratch cycle, leading to additional inflammation and an increased risk for scar formation.²⁸

In 2013, Pelgrift et al²⁹ presented an overview of the anti-inflammatory effects of HOCl and proposed two mechanisms by which the product may reduce pruritus: (a) HOCl is microbicidal to cutaneous pathogens, especially *Staphylococcus aureus*, and (b) is anti-inflammatory, it reduces the activities of histamine, leukotriene B4 (LTB4), and interleukin-2 (IL-2), all of which have been implicated in the pathophysiology of itch.²⁹

In fact, in a recent mouse model study of itch and atopic dermatitis,¹³ investigators found treatment with HOCl hydrogel prevented the development of eczematous lesions and bouts of scratching. Results indicate a direct reduction in sensory response by HOCl leads to significantly reduced itch and inflammation in vivo.¹³ Furthermore, study results indicated 50% of subjects reporting an improvement in pruritus as early as day 1, with 85% of subjects showing significant reductions by day 3 of treatment with HOCl (Figure 4).³⁰

7.3 | Wound perfusion

Oxygen plays a critical role in the formation of collagen, the growth of new capillaries, and the control of infection. Perfusion and delivery of O₂ to tissue are closely related.³¹

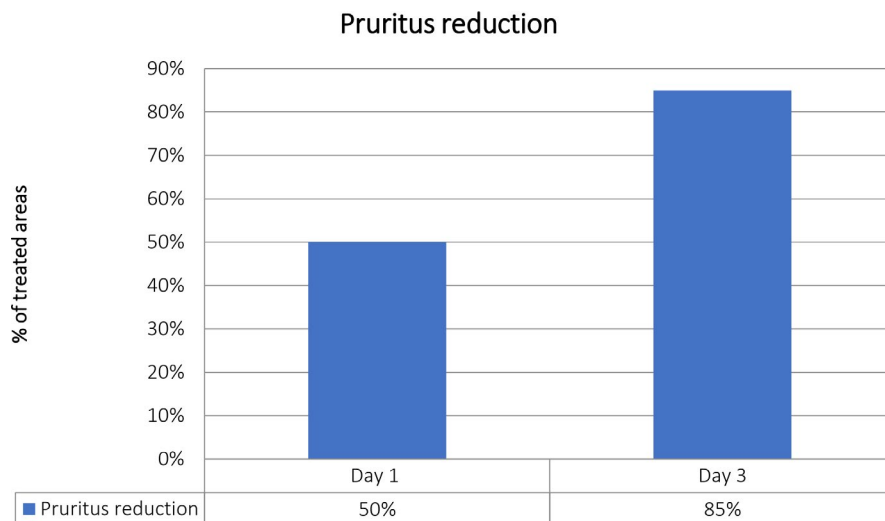
A study by Bongiovanni³² investigated effects of topical HOCl in the treatment of patients with venous leg ulcers, including time to wound healing. By assessing micro-circulatory integrity (oxygenation), the author established most patients had elevated transcutaneous oxygen pressure (TcPO₂) levels in peri-wound tissues 15-30 seconds after exposure to HOCl and continued to have elevated TcPO₂ levels some 72 hours after exposure. All venous wounds treated in the study healed, with time to wound closure ranging from 2 to 5 days to ~180 days.³²

8 | SCAR MANAGEMENT

8.1 | Scar creation

The management of scars is intimately connected to all stages of wound healing, which in turn comprises a multitude of signaling molecules to regulate the complex process of healing on the molecular level. Additionally, continuous collagen production and degradation have an effect of remodeling the mature wound matrix for approximately 6 months postinjury.¹⁴

FIGURE 4 Hypochlorous acid reduced pruritus and pain. Adapted from Draelos et al 2012³⁰



9 | KELOID FORMATION AND HYPERTROPHIC SCARS

Patients with hypertrophic scars (HTS) or keloid formation may have an impaired quality of life specifically from factors including significant itch, pain, and restricted mobility from the scar.³³ Keloids, regardless of the type of injury, share some similarities with HTS, such as development following injury, skin dryness, and itchiness.^{4,15} Recent research suggests both scar types are influenced by chronic inflammation of the reticular dermis.³⁴

In the normal maturation phase, when a wound reaches maturity, extracellular cytokines assist in cessation of further collagen fibers, etc.^{14,34} However, a number of genetic and environmental factors can interfere with this “stop” signal, where the lack of negative feedback leads to a continual production of collagen fibers in the wound (Figure 2).^{14,15} Clinically, this response is observed as a HTS. The proliferation of collagen fibers remains self-contained within the original wound margins in HTS.⁴

Conversely, in keloid formation, the scar hypertrophy continues through the later phase of remodeling, between 6 and 18 months, with uninhibited deposition of collagen growing well beyond original wound margins (Figure 2).^{15,35} Therefore, the panel reiterated, early intervention or even prophylactic use of HOCl after incisional procedures may be key to controlling a hyperplastic response.

10 | TOPICAL HOCL AND SILICONE

Because HOCl is known to impact all three phases of wound healing at the cellular level,^{8,12,36} the combination of HOCl and silicone is being studied for its efficacy in managing and treating HTS and keloids, and for relieving the associated pruritus and pain.^{7,37,38}

Hypochlorous acid is a safe and effective antiseptic for skin and wound disinfection,^{6,8,29} while silicone has been used for over 30 years in scar therapy.³⁷ Even more compelling is that unlike many other

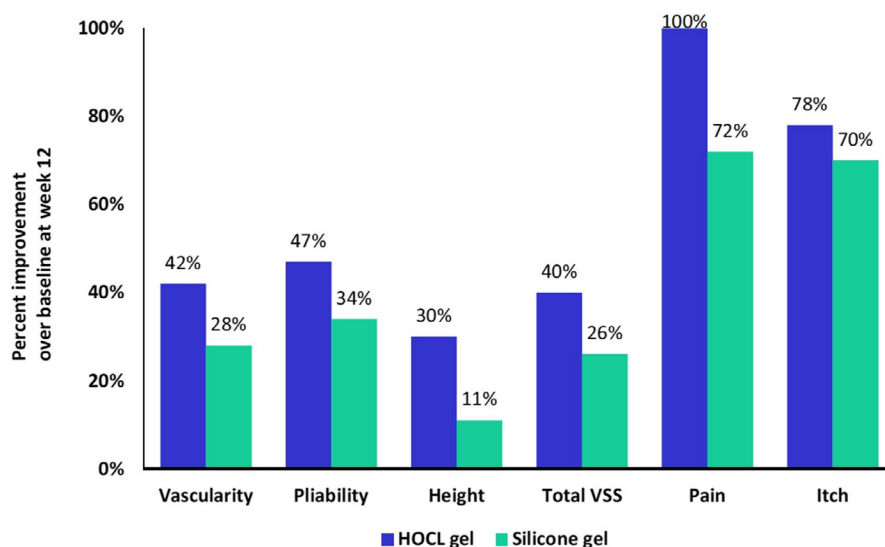


FIGURE 5 Improvement in appearance and symptoms of scars after HOCL use. Adapted from Bucko et al³⁹

TABLE 1 Consensus regarding the use of HOCl and silicone gel

Type of procedure	Product L	Product R/C	Product AQ
Electro-desiccation and curettage Fractional laser	For preprocedure antisepsis, spray on treatment site and instruments. Intraoperative use of the spray to reduce inflammation. After resurfacing use the spray combined with an emollient. For at-home care 3-4 times a day during week 1.	For at-home care combined with L during week 1 then continue R/C for scar management and to reduce pain.	Combine with R/C for moisturization.
Postshave biopsy and second-intention healing sites	For preprocedure antisepsis use the spray on the treatment site and instruments. Intraoperative use to reduce inflammation.	Cleanse 2-3 times per day with L for 1 wk on the face and 2-3 times per week on the body. For facial shave biopsies, use R/C for 2-3 m. Recommended for a min. of 90 d for sites healing by secondary intention. Use for 180 d for open wounds.	Combine with R/C to provide more moisture.
Postsuture removal	For antisepsis and at-home care.	Recommend R/C for a minimum of 90 d postsuture removal in face-lifts to optimize scar.	

Note: Levicyn™/Lasercyn™ [HOCL spray and gel] (L), Regenacyn™/Celacyn™ [HOCl gel and silicone gel] (R/C), Aquaphor®[41% petrolatum] (AQ).

silicone-based products, the combination hydrogel can be applied directly to the wound site in the immediate postoperative period.^{39,40}

Quality of scarring may be improved when postsurgical inflammation and edema is reduced and wound healing is uneventful.¹⁵ Treatment reducing inflammation postprocedure as early as possible can be expected to result in optimal scarring.^{7,15}

Results from a double-blind, multi-center study were presented to the panel regarding HOCl and silicone in a gel formulation vs a 100% silicone topical agent in patients with HTS or keloids.³⁹ The investigators found that pain, itching, vascularity, elasticity, and height of the target scars improved consistently throughout the study for both HOCl and silicone gel and the 100% silicone agent. Trends toward a statistically significant improvement in scar quality compared with baseline were demonstrated for the HOCl and silicone scar management gel (Figure 5).³⁹

Gold et al⁷ also reported on a number of small studies that demonstrated better results with HOCl and modified silicon oil compared to silicone gel regarding appearance of HTS and keloids.⁷ HOCl and silicone gel could be used to treat HTS and keloids early before abnormal scarring begins.

11 | CONSENSUS REGARDING THE USE OF HOCL AND SILICONE GEL

Panel members discussed their clinical experience using HOCl containing products in clinical practice after which they voted and reached consensus. The following products were discussed: Levicyn™/Lasercyn™ [HOCl spray and gel] (L), Regenacyn™/Celacyn™ [HOCl combined with silicone gel] (R/C), and Aquaphor® [41% petrolatum] (AQ).

Product L is available as a spray and gel and may be used for the reduction of inflammation peri-procedurally and for optimal scar formation management in combination with other products.

The panel agreed that the spray is to be used during all phases of injection/laser procedures, from preprocedure (removing excess makeup) through peri-procedure (spraying on the face/cold packs) to long-term postprocedure (infection prevention and stimulating optimal healing). When used after resurfacing, the spray is immediately post-procedure applied and combined with an emollient. For at-home care, the spray is used 3-4 times a day during the first week postprocedure.

The panel members agreed on prescribing product R/C immediately postprocedure and after surgery on sutures for treatment of early scar formation. However, for facelift procedures product use is recommended to start after suture removal and to be continued for a minimum of 90 days. Postshave biopsy, the product is to be used for 30 days, and in case of secondary intent healing wounds, the product is to be used for up to 180 days.

The panel members agreed on recommending that R/C is to be reapplied frequently as it dries out more quickly compared with other silicone-based scar gels.

Petroleum jelly or product AQ may be used in combination with R/C to retain more moisture and to prevent the gel from drying out. Additionally, after suture removal a hydrating sunscreen may be used over product R/C.

It is important to show physicians and patients how/why to use the products for optimal results. At night and when in public, R/C should be applied with AQ or petrolatum jelly on top and covered with a dressing (Table 1).

12 | CONCLUSION

For physicians who perform cosmetic, aesthetic, and medical dermatologic procedures, wound healing and scar management are ongoing challenges; prevention of infection followed by optimal wound care must be followed rigorously to fulfill cosmetically superior

aesthetic outcomes and minimal scars, including HTS and keloids. Panel members acknowledged their own clinical experiences suggest "conventional" options may no longer be ideal. Therefore, the panel concluded, HOCl can be indispensable in pre and peri-procedures as an antiseptic and anti-inflammatory agent, and in post-procedures, including postsutures, as a wound healing agent. Finally, as a scar management agent preventing or minimizing aberrant scar development well into the remodeling phase, HOCl could become the first line pre and peri-procedure antiseptic for supporting wound healing and scar management.

ACKNOWLEDGMENTS

The literature research for this review was supported with an educational grant of IntraDerm Pharmaceuticals

ORCID

Michael H. Gold  <https://orcid.org/0000-0002-5183-5433>

Anneke Andriessen  <https://orcid.org/0000-0001-5930-4162>

Suneel Chilukuri  <https://orcid.org/0000-0002-4331-8305>

REFERENCES

- Robson MC, Payne WG, Ko F, et al. Hypochlorous acid as a potential wound care agent: part II. Stabilized hypochlorous acid: its role in decreasing tissue bacterial bioburden and overcoming the inhibition of infection on wound healing. *J Burns Wounds*. 2007;6:e6.
- Bhatia AH, Hsu J, Schlesinger T, Weiss R. Optimizing wound healing for cosmetic and medical dermatologic procedures. *Practical dermatology*. 2018;1:42-45.
- Duc Q, Breetveld M, Middelkoop E, Scheper RJ, Ulrich MM, Gibbs S. A cytotoxic analysis of antiseptic medication on skin substitutes and autograft. *Br J Dermatol*. 2007;157(1):33-40.
- Chen MA, Davidson TM. Scar management: prevention and treatment strategies. *Curr Opin Otolaryngol Head Neck Surg*. 2005;13(4):242-247.
- Wang L, Bassiri M, Najafi R, et al. Hypochlorous acid as a potential wound care agent: part I. Stabilized hypochlorous acid: a component of the inorganic armamentarium of innate immunity. *J Burns Wounds*. 2007;6:e5.
- Chapman I, Hsu J, Stankiewicz K, Bhatia A. Use of hypochlorous acid as a pre-operative antiseptic before placement of dermal fillers: an alternative to standard options. *Dermatol Surg*. 2017;1-3.
- Gold MH, Andriessen A, Dayan SH, Fabi SG, Lorenc ZP, Henderson Berg MH. Hypochlorous acid gel technology-Its impact on post-procedure treatment and scar prevention. *J Cosmet Dermatol*. 2017;16(2):162-167.
- Sakarya S, Gunay N, Karakulak M, Ozturk B, Ertugrul B. Hypochlorous acid: an ideal wound care agent with powerful microbicidal, antibiofilm, and wound healing potency. *Wounds*. 2014;26(12):342-350.
- Steinsapir KD, Woodward JA. Chlorhexidine keratitis: safety of chlorhexidine as a facial antiseptic. *Dermatol Surg*. 2017;43(1):1-6.
- Norman G, Dumville JC, Crosbie EJ. Antiseptics and antibiotics for surgical wounds healing by secondary intention: summary of a cochrane review. *JAMA Dermatol*. 2016;152(11):1266-1268.
- Bever GJ, Brodie FL, Hwang DG. Corneal Injury from presurgical chlorhexidine skin preparation. *World Neurosurg*. 2016;96(610):e1-e4.
- Biesman B, Cohen JL, Gold MH. Integrating HOCl into wound care: the new paradigm for patient management. *Pract Dermatol Spec Sect: Clin Insights*. 2017;7:1-2.
- Fukuyama T, Martel BC, Linder KE, Ehling S, Ganchingco JR, Baumer W. Hypochlorous acid is antipruritic and anti-inflammatory in a mouse model of atopic dermatitis. *Clin Exp Allergy*. 2018;48(1):78-88.
- Son D, Harijan A. Overview of surgical scar prevention and management. *J Korean Med Sci*. 2014;29(6):751-757.
- Gauglitz GG, Korting HC, Pavicic T, Ruzicka T, Jeschke MG. Hypertrophic scarring and keloids: pathomechanisms and current and emerging treatment strategies. *Mol Med*. 2011;17(1-2):113-125.
- James GA, Swogger E, Wolcott R, et al. Biofilms in chronic wounds. *Wound Repair Regen*. 2008;16(1):37-44.
- Kruse CR, Nuutila K, Lee CC, et al. The external microenvironment of healing skin wounds. *Wound Repair Regen*. 2015;23(4):456-464.
- Fazli M, Bjarnsholt T, Kirketerp-Moller K, et al. Quantitative analysis of the cellular inflammatory response against biofilm bacteria in chronic wounds. *Wound Repair Regen*. 2011;19(3):387-391.
- Grice EA, Segre JA. Interaction of the microbiome with the innate immune response in chronic wounds. *Adv Exp Med Biol*. 2012;946:55-68.
- Vissers MC, Winterbourn CC. Oxidation of intracellular glutathione after exposure of human red blood cells to hypochlorous acid. *Biochem J*. 1995;307(Pt 1):57-62.
- Winterbourn CC, Kettle AJ. Redox reactions and microbial killing in the neutrophil phagosome. *Antioxid Redox Signal*. 2013;18(6):642-660.
- Knox WE, Stumpf PK, Green DE, Auerbach VH. The inhibition of sulfhydryl enzymes as the basis of the bactericidal action of chlorine. *J Bacteriol*. 1948;55(4):451-458.
- Barrette WC Jr, Albrich JM, Hurst JK. Hypochlorous acid-promoted loss of metabolic energy in *Escherichia coli*. *Infect Immun*. 1987;55(10):2518-2525.
- McKenna SM, Davies KJ. The inhibition of bacterial growth by hypochlorous acid. Possible role in the bactericidal activity of phagocytes. *Biochem J*. 1988;254(3):685-692.
- Ortega-Pena S, Hidalgo-Gonzalez C, Robson MC, Krotzsch E. In vitro microbicidal, anti-biofilm and cytotoxic effects of different commercial antiseptics. *Int Wound J*. 2017;14(3):470-479.
- Medina-Tamayo J, Sanchez-Miranda E, Balleza-Tapia H, et al. Super-oxidized solution inhibits IgE-antigen-induced degranulation and cytokine release in mast cells. *Int Immunopharmacol*. 2007;7(8):1013-1024.
- Dharap SB, Ghag GS, Kulkarni KP, Venkatesh V. Efficacy and safety of oxum in treatment of the venous ulcer. *J Indian Med Assoc*. 2008;106(5):326, 8-30.
- Parnell LKS. Itching for Knowledge about wound and scar pruritus. *Wounds*. 2018;30(1):17-36.
- Pelgrift R, Friedman AJ. Topical hypochlorous acid (HOCl) as a potential treatment of pruritus. *Curr Derm Rep*. 2013;2:181-190.
- Draeos Z, Cash K. Evaluation of a gel formulation of hypochlorous acid and sodium hypochlorite to reduce pruritus in mild to moderate atopic dermatitis. *Winter Clinical*. 2012;103:624-628.
- Whitney JD. The influence of tissue oxygen and perfusion on wound healing. *AACN Clin Issues Crit Care Nurs*. 1990;1(3):578-584.
- Bongiovanni CM. Effects of hypochlorous acid solutions on venous leg ulcers (VLU): experience With 1249 VLUs in 897 patients. *J Am Coll Clin Wound Spec*. 2014;6(3):32-37.
- English RS, Shenefelt PD. Keloids and hypertrophic scars. *Dermatol Surg*. 1999;25(8):631-638.
- Song R, Bian HN, Lai W, Chen HD, Zhao KS. Normal skin and hypertrophic scar fibroblasts differentially regulate collagen and fibronectin expression as well as mitochondrial membrane potential in response to basic fibroblast growth factor. *Braz J Med Biol Res*. 2011;44(5):402-410.

35. Wolfram D, Tzankov A, Pulzl P, Piza-Katzer H. Hypertrophic scars and keloids—a review of their pathophysiology, risk factors, and therapeutic management. *Dermatol Surg*. 2009;35(2):171-181.
36. Chen CJ, Chen CC, Ding SJ. Effectiveness of hypochlorous acid to reduce the biofilms on titanium alloy surfaces in vitro. *Int J Mol Sci*. 2016;17(7):1-12.
37. Bleasdale B, Finnegan S, Murray K, Kelly S, Percival SL. The use of silicone adhesives for scar reduction. *Adv Wound Care (New Rochelle)*. 2015;4(7):422-430.
38. Goldberg DJ. Efficacy and safety of a novel 100% silicone scar gel treatment for early intervention in scar management. *J Clin Aesthet Dermatol*. 2016;9(12):13-20.
39. Bucko A, Draelos ZD, Dubois JC, Jones TM. A double-blind, randomized study to compare Microcyn® scar management hydrogel, K103163, and Kelo-cote scar gel for hypertrophic or keloid scars. Topical gel for hypertrophic and keloid scars. *Dermatologist*. 2015;23:113-122.
40. Landsman A, Blume PA, Jordan DA Jr, Vayser D, Gutierrez A. An open-label, three-arm pilot study of the safety and efficacy of topical microcyn Rx wound care versus oral levofloxacin versus combined therapy for mild diabetic foot infections. *J Am Podiatr Med Assoc*. 2011;101(6):484-496.

How to cite this article: Gold MH, Andriessen A, Bhatia AC, et al. Topical stabilized hypochlorous acid: The future gold standard for wound care and scar management in dermatologic and plastic surgery procedures. *J Cosmet Dermatol*. 2020;00:1–8. <https://doi.org/10.1111/jocd.13280>